

## Case Report

### Corresponding author

Fatima Tiwana, BDS, DDS

Department of Periodontics and  
Dental Hygiene

University of Detroit Mercy

School of Dentistry

Detroit, Michigan 48202, USA

Tel. 1 (248) 961-9997

Fax: 1 (313) 494-6666

E-mail: [tiwanafa@udmercy.edu](mailto:tiwanafa@udmercy.edu)

Volume 2 : Issue 5

Article Ref. #: 1000DOJ2124

### Article History

Received: December 26<sup>th</sup>, 2015

Accepted: February 25<sup>th</sup>, 2016

Published: February 26<sup>th</sup>, 2016

### Citation

Tiwana F, Janic A, Wheeler M, Kinaia B. A rare oral focal mucinosis presentation in the aesthetic zone: A case report. *Dent Open J.* 2016; 2(5): 132-136. doi: [10.17140/DOJ-2-124](https://doi.org/10.17140/DOJ-2-124)

### Copyright

©2016 Tiwana F. This is an open access article distributed under the Creative Commons Attribution 4.0 International License (CC BY 4.0), which permits unrestricted use, distribution, and reproduction in any medium, provided the original work is properly cited.

# A Rare Oral Focal Mucinosis Presentation in the Aesthetic Zone: A Case Report

Fatima Tiwana, BDS, DDS<sup>1</sup>; Ana Janic, DDS, MS<sup>2</sup>; Michelle Wheeler, PhD<sup>3</sup>; Bassam Kinaia, DDS, CAGS, MS<sup>2</sup>

<sup>1</sup>Graduate Periodontics Program - Department of Periodontology and Dental Hygiene, University of Detroit Mercy School of Dentistry, Detroit, MI, USA

<sup>2</sup>Department of Periodontology and Dental Hygiene, University of Detroit Mercy School of Dentistry, Detroit, MI, USA

<sup>3</sup>Department of Biomedical and Diagnostic Sciences, University of Detroit Mercy School of Dentistry, Detroit, MI, USA

## ABSTRACT

The current case report presents a rare oral pathology of Oral Focal Mucinosis (OFM). The patient developed marginal gingival inflammation subsequent to esthetic crown lengthening surgery. The differential diagnosis included candidal infection, foreign body gingivitis, and Desquamative Gingivitis (DG). An incisional biopsy was performed, indicating a definitive histopathological diagnosis of OFM. OFM is a lesion developing due to over production of hyaluronic acid by fibroblasts, compromising the normal collagen production. Treatment of OFM is excisional biopsy, however; its location near the gingival margin in the aesthetic zone required a minimally invasive surgical approach. Therefore, a less invasive treatment using corticosteroids was administered, leading to resolution of the inflammation.

**KEYWORDS:** Histology; Pathology; Aesthetic; Crown lengthening; Osseous; Surgery; Mucinoses; Rare diseases; Complications.

## INTRODUCTION

Oral Focal Mucinosis (OFM) is an asymptomatic, benign soft tissue lesion of unknown etiology.<sup>1-3</sup> It presents as a pedunculated or sessile growth with most cases occurring in women. OFM involves the keratinized oral mucosa, with 80% of the lesions developing on the gingiva and the remainder on the palate. Although Tomich<sup>3</sup> first reported 8 cases of the lesions as the oral counterpart of cutaneous focal mucinosis, it is now recognized that OFM is a separate clinical entity. Bharti and Singh<sup>4</sup> stated that 57 cases of OFM have been reported in the English literature and 3 in the Indian literature. To date a total of approximately 70 cases of oral focal mucinosis have been reported in the literature.<sup>3-17</sup>

OFM lesions are difficult to diagnose because they have no distinct clinical features. Therefore, they are often diagnosed as gingival hyperplasia, fibroma, pyogenic granuloma or fibrous epulis.<sup>1-18</sup> Histopathology of OFM shows a focal myxoid degeneration of the connective tissue, possibly due to the over production of hyaluronic acid by fibroblasts during collagen production, and is the definitive diagnosis for OFM.<sup>2</sup> In the current case report, OFM occurred after a routine crown lengthening procedure with clinical presentation resembling that of Desquamative Gingivitis (DG).

## CASE REPORT

### Initial Presentation

A 29 year-old healthy female presented to the Graduate Periodontics Clinic at the University of Detroit Mercy (UDMSD) with chief complaint: "My teeth are too short." The pa-

tient presented with provisional crowns on teeth #7, 8, 9, and 10 (Figure 1). The dental history revealed root canal treatment and Porcelain Fused to Metal crowns (PFM). The clinical and radiographic evaluations revealed altered passive eruption<sup>19</sup> with impingement on biologic width (Figure 2).<sup>20</sup> The treatment plan included esthetic crown lengthening to increase the clinical crown length to achieve an esthetically pleasing smile.

### Surgical Phase

Teeth wax up was performed to determine the new clinical crowns dimensions and a surgical guide was made. Esthetic crown lengthening was performed for teeth #4 through #12 following the new clinical crowns dimensions. The surgical area was closed using single interrupted vicryl sutures (Ethicon Inc., Somerville, NJ, USA) and the flap stabilized with a poly-ether urethane dimethacrylate resin-based dressing (Barricade, Dentsply International Inc., Milford, DE, USA). The patient was discharged in good condition and given post-operative instructions and Ibuprofen 800 mg and Chlorhexidine 0.12% mouth wash prescriptions. The dressing was removed 2 weeks post-surgery.

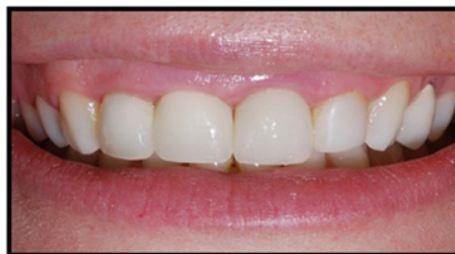### Follow-Up Phase

At five weeks post-surgery, the patient presented with a severe well-demarcated gingival erythematous lesion close to

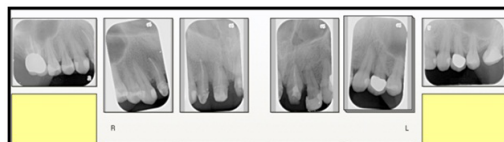the free gingival margin of the surgical area (Figure 3). Although the patient had no known allergies, it was thought that an allergic reaction to methacrylate had occurred. Differential diagnoses included candidal infection, foreign body gingivitis and DG. The patient was advised to have a biopsy performed but declined. The patient was prescribed Magic Mouthwash consisting of five ingredients in a 1:1:1:1:1 ratio: Kaopectate (anti-acid coating agent), Nystatin (anti-fungal), Diphenhydramine (anti-histamine), Lidocaine (anesthetic) and Prednisolone (anti-inflammatory), with instructions to use the mouth rinse 4 to 5 times per day.

At eight weeks post-surgery (after two weeks of using the mouthwash), adequate healing of the soft tissues occurred but the lesion was still present at the gingival margin extending from tooth #5 to #9. The patient was referred to an allergist to rule out reaction to the periodontal dressing. The test was negative to the dressing but the patient tested positive to nickel allergy. Since periosteal elevators have trace elements of nickel, it is possible that some shavings were embedded in the soft tissues during the crown lengthening surgery. The patient was prescribed systemic Prednisolone 5 mg for 15 days. Dosage instructions were 5mg every 6 hours for 5 days tapered down to every 12 hours for another 5 days and finally once a day for the last 5 days.

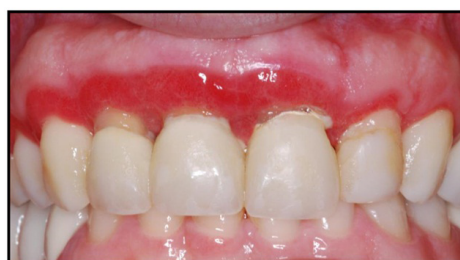At 12 weeks post-surgery marked improvement was observed but the lesion had not completely resolved (Figure 4).



**Figure 1:** Clinical image at initial presentation shows a high "gummy" smile with provisional crowns.



**Figure 2:** Periapical radiographs showing impingement of the biological width.



**Figure 3:** At five weeks post-surgery and three weeks post-Barricade dressing removal, the patient presented with severe gingival erythema mimicking desquamative gingivitis (DG).

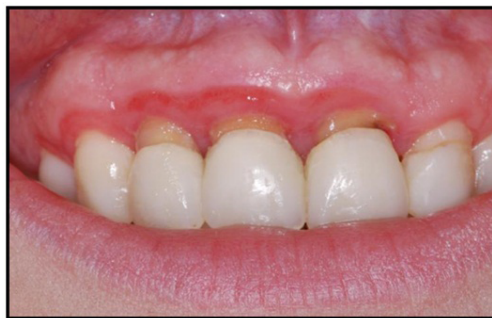Adult dental prophylaxis was performed followed by gingivoplasty under local anesthesia from #5 to #9. After two weeks, Triamcinolone acetonide 0.1% corticosteroid (Kenalog® in Orabase® Bristol-Myers Squibb Company Princeton, NJ, USA) *via* tray was prescribed and significant reduction in erythema occurred. Five months post-aesthetic crown lengthening procedure and medications, the patient received permanent porcelain crowns for teeth #7, 8, 9, and 10. At 1 year post-surgery, the erythematous lesion was reduced but slightly evident on teeth #8 and #9 (Figure 5). Biopsy was re-advised to the patient to determine the etiology of the lesion, and the patient consented to treatment. An incisional biopsy was performed obtaining specimens from the facial gingival margins of teeth #8 and #9 (Figure 6). At 18 days post-biopsy the erythema was still present.

### Histological Analysis

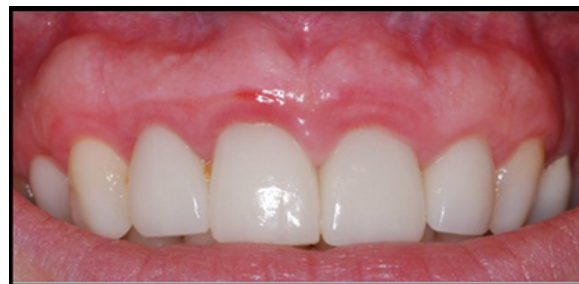Three biopsy specimens were submitted for analysis

(Immco Diagnostics, Buffalo, NY, USA). The first specimen in formalin fixation with hematoxylin and eosin staining was not consistent with immunologically recognizable autoimmune-mediated blistering diseases and therefore the suspected diagnosis was DG (Figure 7). The second and third specimens were submitted for immunofluorescence analysis. The specimens were taken from the gingiva of #9 and processed for immunofluorescence microscopy to analyze *in vivo* deposits of IgG, IgG4, IgA, IgM, fibrin and complement C3. The specimens were denuded of surface epithelium while the surrounding normal mucosa showed an intact epithelium. Immunofluorescence analysis revealed no significant deposits of immunoglobulin, complement C3 or fibrin. The histopathological diagnosis was oral focal mucinosis.

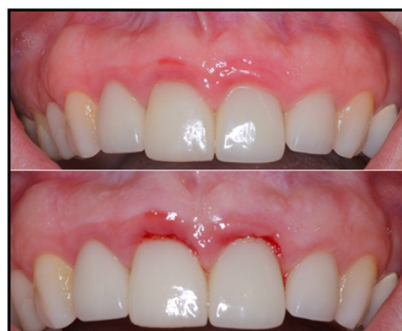Although excisional biopsy has been proposed as the correct treatment for oral focal mucinosis, this was not performed in this case. Rather, incisional biopsy was performed due to the



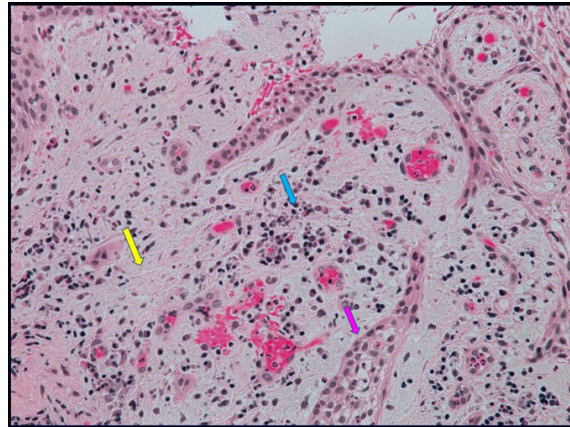
**Figure 4:** At 12 weeks post-surgery, and after using systemic Prednisolone for 15 days, the lesion was improved but had still not resolved.



**Figure 5:** One year, post-crown lengthening with All-Porcelain permanent crowns. After one year the erythematous lesion was significantly reduced.



**Figure 6:** The upper image shows pre-incisional biopsy and the lower image shows immediately post-biopsy from gingival margins of #8 and #9.



**Figure 7:** Light microscopy analysis of formalin-fixed and hematoxylin and eosin-stained biopsy specimen showing myxoid stroma (Yellow arrow) and abundance of fibroblasts (Blue arrow). Epithelium is also evident (Pink arrow) at 20X magnification.

aesthetic location and size of the lesion.

## DISCUSSION

Oral focal mucinosis has been reported intraorally at various locations, with the gingiva and hard palate being the most common sites. Most of the reported cases have occurred in females. Tomich<sup>3</sup> described it as an oral counterpart of cutaneous focal mucinosis, but in later reports it has emerged as a distinct entity. Although its definitive diagnosis is based on histopathology, a common finding is that its clinical presentation is mostly on keratinized tissue overlying bone. Clinical differential diagnosis of OFM cases reported has varied in the literature and includes fibrous hyperplasia, giant cell fibroma, peripheral giant cell granuloma, peripheral ossifying fibroma, peripheral odontogenic fibroma, squamous papilloma, mucocele and pyogenic granuloma.<sup>1-18</sup> To the authors knowledge, this is the first case reported where OFM has resembled the appearance of DG.

Periodontal esthetic crown lengthening surgery is comprised of osteotomy and osteoplasty. Osseous re-contouring inflicts trauma to the periodontal tissues and may have contributed to the development of the lesion in this case. There is controversy as to whether local trauma plays a role in the etiology of OFM. While Tomich hypothesized that trauma may not be related to OFM,<sup>3</sup> while Gnepp et al<sup>18</sup> claimed that trauma may be a contributing factor for the development of OFM soft tissue lesions. In support of the latter, Neto et al<sup>8</sup> suggested that fibroblasts stimulated by trauma from surgically assisted rapid maxillary expansion produced hyaluronic acid, not osteoid tissues and caused oral focal mucinosis in a young female patient. Lesions on the marginal gingiva occurring on the maxillary facial aspect can be challenging to treat, with esthetics being a major concern. Even though excisional biopsy is the treatment of choice for OFM, in the present case gingivoplasty was performed. Gingivectomy was not the appropriate treatment of choice because of aesthetics. The marginal erythema significantly subsided at one-year follow up.

## CONCLUSION

OFM may be considered in the differential of yet another clinical lesion, namely desquamative gingivitis (DG). The literature has reported many different forms of OFM but the diagnosis can only be confirmed with histopathology. The current case report highlights oral focal mucinosis as a viable differential diagnosis when evaluating a clinical appearance consistent with desquamative gingivitis (DG).

## ACKNOWLEDGEMENTS

The authors thank Dr. Lakshmanan Suresh for histopathological consultation.

**SOURCES OF SUPPORT:** None.

## CONFLICTS OF INTEREST

The authors declare that they have no conflicts of interest.

## CONSENT

The patient has provided written permission for publication of the case details and images.

## REFERENCES

1. Manor Y, Merdinger O, Katz J, Taicher S. Unusual peripheral odontogenic tumors in the differential diagnosis of gingival swelling. *J Clin Periodontol.* 1999; 26: 806-809. doi: [10.1111/j.1600-051X.1999.tb02524.x](https://doi.org/10.1111/j.1600-051X.1999.tb02524.x)
2. Neville BW, Damm DD, Allen CM, Bouquot JE. *Oral and maxillofacial pathology.* 2<sup>nd</sup> ed. Philadelphia, Pennsylvania, USA: Elsevier; 2002: 446.
3. Tomich CE. Oral focal mucinosis: A clinicopathologic and histochemical study of eight cases. *Oral Surg Oral Med Oral Pathol.*

- 1974; 38(5): 714-724. doi: [10.1016/0030-4220\(74\)90392-2](https://doi.org/10.1016/0030-4220(74)90392-2)
4. Bharti V, Singh J. Oral focal mucinosis of palatal mucosa: A rare case report. *Contemp Clin Dent*. 2012; 3(Suppl 2): S214-S218. doi: [10.4103/0976-237X.101098](https://doi.org/10.4103/0976-237X.101098)
5. Ena S, Nadellamanjari, Chatterjeeanirban, Ramesh A. Oral focal mucinosis: A rare case report of two cases. *Ethiop J Health Sci*. 2013; 23(2): 178-182.
6. Lee JG, Allen G, Moore L, Gue S. Oral focal mucinosis in an adolescent: a case report. *Aust Dent J*. 2012; 57(1): 90-92. doi: [10.1111/j.1834-7819.2011.01649.x](https://doi.org/10.1111/j.1834-7819.2011.01649.x)
7. Bosco AF, Macarini VC, de Almeida JM, et al. Oral focal mucinosis: clinical case presentation with a focus on esthetic and functional surgical resolution. *Clin Adv Periodont*. 2014; 4(4): 251-255. doi: [10.1902/cap.2013.130018](https://doi.org/10.1902/cap.2013.130018)
8. Neto JR, Sendyk M, Uchida LM, Nunes FD, de Paiva JB. Oral focal mucinosis associated with surgically assisted rapid maxillary expansion. *Am J Orthod Dentofacial Orthop*. 2014; 45(4): 534-538. doi: [10.1016/j.ajodo.2013.02.035](https://doi.org/10.1016/j.ajodo.2013.02.035)
9. Kumar SM, Kumar HM, Sivakumar V, Kumar SH. A diagnostic challenge: pyogenic granuloma or oral focal mucinosis. *BMJ Case Rep*. 2015; pii: bcr2015210150. doi: [10.1136/bcr-2015-210150](https://doi.org/10.1136/bcr-2015-210150)
10. Woo J, Cheung WS. Bilateral oral focal mucinosis on the palate of a 2-year-old child: A case report. *Int J Paediatr Dent*. 2015; 25(1): 70-72.
11. Gonzaga AKG, da Silva Filho TJ, de Oliveira DHIP, de Sousa Lopes MLD, Queiroz LMG, da Silveria EJD. Oral focal mucinosis: Report of 2 cases with histochemical and immunohistochemical analysis. *Oral Surg Oral Med Oral Pathol Oral Rad*. 2015; 2: e70-e71.
12. Joshi CP, Dani NH, Mahale SA, Patel NR. A case of oral focal mucinosis of gingiva: Lesion in disguise. *J Indian Soc Periodontol*. 2015; 19(5): 586-588.
13. Sowmya GV, Manjunatha BS, Nahar P, Aggarwal H. Oral focal mucinosis: A rare case with literature review. *BMJ Case Rep*. 2015; 2015: bcr2014208321. doi: [10.1136/bcr-2014-208321](https://doi.org/10.1136/bcr-2014-208321)
14. Soares de Lima AA, Naval Machado MA, Martins WD, et al. Oral focal mucinosis. *Quintessence Int*. 2008; 39: 611-615.
15. Madhusudhan AS, Nagarajappa D, Manjunatha BS, Saawarn Swati, CharanBabu HS. Oral focal mucinosis: Report of two cases. *Rev Odonto Cienc*. 2010; 25: 310-313.
16. Aldred MJ, Talacko AA, Ruljancich K. Oral focal mucinosis; report of 15 cases and review of the literature. *Pathology*. 2003; 35: 393-396.
17. Soda G, Baiocchini A, Bosco D, Nardoni S, Melis M. Oral focal mucinosis of the tongue. *Pathol Oncol Res*. 1998; 4: 304-307.
18. Gnepp DR, Vogler C, Sotelo-Avila C, Kielmovitch IH. Focal mucinosis of the upper aerodigestive tract in children. *Hum Pathol*. 1990; 21(8): 856-858. doi: [10.1016/0046-8177\(90\)90056-B](https://doi.org/10.1016/0046-8177(90)90056-B)
19. Coslet JG, Vanarsdall R, Weisgold A. Diagnosis and classification of delayed passive eruption of the dentogingival junction in the adult. *Alpha Omegan*. 1977; 70(3): 24-28.
20. Gargiulo AW, Wentz FM, Orban B. Dimensions and relations of the dentogingival junction in humans. *J Periodontol*. 1961; 32: 261-267. doi: [10.1902/jop.1961.32.3.261](https://doi.org/10.1902/jop.1961.32.3.261)