

Editorial

***Corresponding author**
Alessandro Arrigo, MD

Department of Biomedical Sciences and
Morphological and Functional Imaging
University of Messina
Via Consolare Valeria
1 Messina 98125, Italy
E-mail: alessandro.arrigo@hotmail.com

Volume 1 : Issue 1

Article Ref. #: 1000ROJ1e002

Article History

Received: January 22nd, 2016

Accepted: January 25th, 2016

Published: January 25th, 2016

Citation

Arrigo A, Calamuneri A, Mormina E. MRI investigation of optic radiations in human brain: new findings and technical considerations. *Radiol Open J.* 2016; 1(1): e6-e10. doi: [10.17140/ROJ-1-e002](https://doi.org/10.17140/ROJ-1-e002)

Copyright

©2016 Arrigo A. This is an open access article distributed under the Creative Commons Attribution 4.0 International License (CC BY 4.0), which permits unrestricted use, distribution, and reproduction in any medium, provided the original work is properly cited.

MRI Investigation of Optic Radiations in Human Brain: New Findings and Technical Considerations

Alessandro Arrigo*, Alessandro Calamuneri and Enricomaria Mormina

Department of Biomedical Sciences and Morphological and Functional Images, University of Messina, Messina, Italy

KEYWORDS: Optic radiations; Tractography; Diffusion MRI; DTI; CSD.

ABBREVIATIONS: ORs: Optic Radiations; LGN: Lateral Geniculate Nucleus; DTI: Diffusion Tensor Imaging; MRI: Magnetic Resonance Imaging; HARDI: High Angular Resolution Diffusion-weighted Imaging; QBI: Q Ball Imaging; DSI: Diffusion Spectrum Imaging; CSD: Constrained Spherical Deconvolution; WM: White Matter; FA: Fractional Anisotropy.

Optic Radiations (ORs) are two white matter fiber bundles allowing direct connection between homolateral Lateral Geniculate Nucleus (LGN) and visual cortex. From the anatomical point of view, ORs are conventionally divided in three different portions, namely anterior, middle and posterior; the Meyer's loop represents the anterior portion, and it has been shown to be a bundle with a very high variability in human brain.¹⁻³ The latter aspect has to be taken into account when studying ORs in clinical and surgical contexts. Indeed, ORs represent eloquent white matter bundles often reconstructed by means of Magnetic Resonance Imaging (MRI) based approaches in order to assess their involvement by pathological conditions as well as to prevent post-surgical damages. Both these conditions can compromise visual function by causing, for instance, visual field deficits.^{4,5} Schematic representation of ORs' bundles and common visual field deficits associated with ORs' lesions is shown in Figure 1.

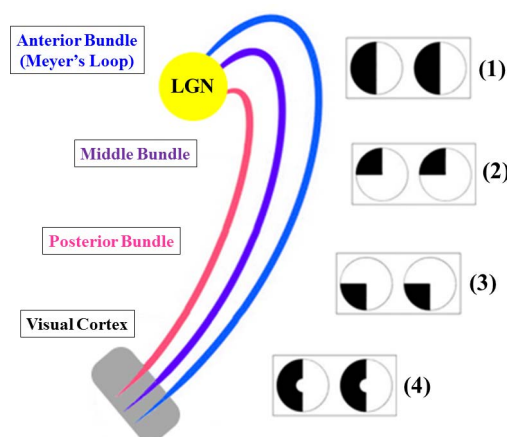


Figure 1: Schematic representation of ORs, from their origin from LGN (yellow) to visual cortex (grey) and common visual field deficits associated with ORs' lesions. Each bundle is colored separately. LGN's damage is followed by homonymous hemianopia (1). Lesions of the anterior bundle (blue) cause homonymous superior quadrantanopia (2) whereas damages of the posterior bundle (pink) are followed by homonymous inferior quadrantanopia (3). Middle bundle is shown in violet. Homonymous hemianopia with macular sparing can be seen after damages at visual cortex level (4).

ORs are largely studied by means of diffusion MRI based modelling techniques, such as Diffusion Tensor Imaging (DTI). These methods allow both qualitative evaluation

of white matter bundles as well as quantitative analysis of several diffusion parameters, such as Fractional Anisotropy. The non-invasive investigation of ORs by means of diffusion MRI has provided several morphological information regarding ORs' connectivity. In particular, moving beyond well demonstrated link with V1 and V2,⁶ direct connections with V3,⁷ V4⁸ and V5^{8,9} have been recently shown. Functional implications of such connectivity include both primary visual signal elaboration as well as more complex functions; for example, direct connection with extra-striatal areas have been supposed to be implicated in the genesis of complex functional phenomena such as blindsight.¹⁰ Moreover, other studies have hypothesized that such extra-striate connectivity might be the anatomical basis for the functional compensation performed after damages of striate visual cortex.¹¹

In the context of tractographic driven investigation of ORs, several issues should be considered, especially if using conventional DTI. Indeed, ORs reconstruction might be potentially affected by well-known DTI limitations, such as partial volume effects.^{12,13} Furthermore, several bundle-specific issues may compromise ORs tractographic reconstructions, e.g. complexity of ORs anatomical course as well as their relationship with other white matter bundles and brain structures.^{1,2,8,14,15} From a technical perspective, several voxels with complex geometries may be involved, which are known to cause an inaccurate analysis when applying DTI model. These potential pitfalls raised several criticisms regarding reliability of tractographic findings regarding both ORs detection as well as extrastriate connectivity.¹⁶ To overcome these limitations, other diffusion models have been tested to improve tractographic reconstructions, such as High Angular Resolution Diffusion-weighted Imaging (HARDI), Q Ball Imaging (QBI) and Diffusion Spectrum Imaging (DSI) algorithms. Although tractographic output provided by these approaches was found to outperform DTI based one, these algorithms are however difficult to be applied in clinical contexts because they are really scanner demanding and time-consuming or they showed poor angular resolution.^{17,18} From this point of view, Constrained Spherical Deconvolution (CSD)¹⁸ has been found a powerful technique feasible in clinical settings. Recently, Arrigo and colleagues⁸ have shown how the use of CSD model combined with probabilistic tractography provided robust ORs detection in healthy human brain. They were able to provide a more complete reconstruction of all ORs' portion, especially in case of Meyer's loop, justifying such result as being due to the higher angular resolution reached by CSD if compared to other models, as well as its ability to resolve voxels with complex fibers' configurations.^{8,13,18} These voxels are indeed known to represent more than 90% of the total number in each brain, thus causing DTI reconstruction troubles for other eloquent bundles of White Matter (WM), such as corticospinal tract and arcuate fasciculus.¹⁹ It is worthy to note that CSD has been already used to reconstruct ORs, providing accurate tracking of these white matter bundles and increasing reliability and details of ORs morphological profile.^{20,21}

Arrigo et al⁸ reinforced the hypothesis of ORs' extrastriate connectivity as well as their involvement in higher order visual functions. Moreover, direct LGN connection with V4 was shown for the first time in humans, reinforcing the findings provided by previous analyses performed in animals.^{22,23} The comparative view of DTI based and CSD based ORs reconstructions is shown in Figure 2.

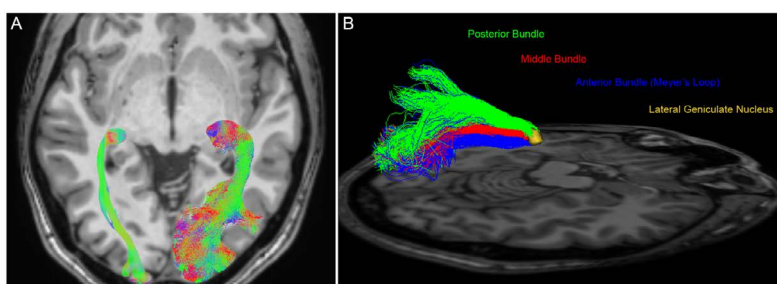


Figure 2: OR tractographic reconstruction in healthy human brain. (A) Axial view of DTI based (left side of the image) and CSD based (right side of the image) tractographic reconstructions showed a more complete ORs detection provided by CSD. Each bundle was colored according to its main diffusion direction. (B) Tridimensional sagittal view of CSD based reconstruction of left ORs. The use of CSD based tractography allowed a good detection of each ORs component. Anterior, middle and posterior ORs bundle, starting from LGN (yellow volume), were manually colored respectively in blue, red and green.

If benefits provided by CSD model are important in physiological contexts, they become extremely important in pathological ones, for instance during pre-surgical planning. Indeed, ORs are investigated both in patients with brain neoplasms as well as for surgical treatment of drug-resistant epilepsy, the latter consisting in the anterior temporal lobe resection.^{3,24-27} Regarding brain neoplasms, many additional reconstruction's issues have been shown in these patients, which are caused by neoplasm's effects on diffusion signal; these potential pitfalls may be overcome by using more advanced diffusion signal modelling techniques, such as CSD, as previously reported in other studies.^{28,29} Regarding pre-surgical planning of ORs, the use of CSD based tractography may increase definition of safety resection margins and it might have a good impact on post-surgical visual deficits.

From a quantitative point of view, the adoption of more advanced diffusion based approaches might have an impact on

evaluation of diffusion parameters. Indeed, when performing a tract based quantitative analysis, it should be taken into account that DTI would exclude voxels with complex geometry, since they often show Fractional Anisotropy (FA) values below a relative cut-off used for conventional tracking.¹³ FA decrements can be found both in voxels with multiple orientations and in voxels involved by a pathological process.³⁰ The result of this DTI limitation is the loss of these voxels from the total count, determining an incomplete profiling of a given pathway. With respect to ORs, this issue may particularly affect Meyer's loop, which is known to be poorly detected when using DTI tractography; moreover, also other ORs' portions might be potentially affected due to the presence of crossing fibers.⁸

Performing diffusion parameters evaluation on the basis of CSD outcome may instead allow a more complete quantitative profile of ORs, thus allowing a better depiction of white matter integrity loss, like it has already been previously shown for other brain pathways.^{13,28,29} A reliable quantitative evaluation is required for ORs evaluation in several diseases. Indeed, if ORs are directly involved in case, for instance, of neoplasms or multiple sclerosis, there exist a number of studies showing that that ORs can suffer from damages localized at other levels of the visual system as well, such as primitive optic nerve diseases. In particular, ORs diffusion parameters were found altered both in cases of glaucoma and optic neuritis.³¹⁻³³ These studies suggested that, although we are in presence of a localized damage, the entire visual system should be analyzed in order to assess possible negative effects on other visual structures. From this point of view, advanced methods such as CSD based tractography can be considered powerful tools for a deeper investigation of visual system damages.

This brief description attempted to summarize recent anatomical and physiological advances regarding ORs detection and analysis. Moreover, it showed how advanced diffusion signal modelling techniques may improve ORs' investigation both in healthy and pathological conditions, describing common as well as tract-specific diffusion issues. Furthermore, this study shows that the choice of diffusion model may have a huge impact both on qualitative and quantitative analysis of ORs.

CONFLICTS OF INTEREST

The authors declare that they have no conflicts of interest.

REFERENCES

1. Párraga RG, Ribas GC, Welling LC, et al. Microsurgical anatomy of the optic radiation and related fibers in 3-dimensional images. *Neurosurgery*. 2012; 71(Suppl 1): 160-171. doi: [10.1227/NEU.0b013e3182556fde](https://doi.org/10.1227/NEU.0b013e3182556fde)
2. Pujari VB, Jimbo H, Dange N, et al. Fiber dissection of the visual pathways: analysis of the relationship of optic radiations to lateral ventricle: a cadaveric study. *Neurol India*. 2008; 56(2): 133-137. doi: [10.4103/0028-3886.41989](https://doi.org/10.4103/0028-3886.41989)
3. Nilsson D, Starck G, Ljungberg M, et al. Intersubject variability in the anterior extent of the optic radiation assessed by tractography. *Epilepsy Res*. 2007; 77(1): 11-16. doi: [10.1016/j.eplepsyres.2007.07.012](https://doi.org/10.1016/j.eplepsyres.2007.07.012)
4. Longo D, Fauci A, Kasper D, et al. Harrison's Principles of Internal Medicine. 18th ed. McGraw-Hill Professional, 2011: 1 and 2.
5. Greenberg D, Aminoff M, Simon R. Clinical Neurology 8/E. McGraw-Hill Professional, 2012.
6. Baldwin MK, Kaskan PM, Zhang B, et al. Cortical and subcortical connections of V1 and V2 in early postnatal macaque monkeys. *J Comp Neurol*. 2012; 520(3): 544-569. doi: [10.1002/cne.22732](https://doi.org/10.1002/cne.22732)
7. Alvarez I, Schwarzkopf DS, Clark CA. Extrastriate projections in human optic radiation revealed by fMRI-informed tractography. *Brain Struct Funct*. 2015; 220(5): 2519-2532. doi: [10.1007/s00429-014-0799-4](https://doi.org/10.1007/s00429-014-0799-4)
8. Arrigo A, Calamuneri A, Mormina EM, et al. New Insights in the optic radiations connectivity in the human brain. *Invest Ophthalmol Vis Sci*. 2016; 57(1): 1-5. doi: [10.1167/iops.15-18082](https://doi.org/10.1167/iops.15-18082)
9. Bridge H, Thomas O, Jbabdi S, Cowey A. Changes in connectivity after visual cortical brain damage underlie altered visual function. *Brain*. 2008; 131: 1433-1444. doi: [10.1093/brain/awn063](https://doi.org/10.1093/brain/awn063)
10. Schmid MC, Mrowka SW, Turchi J, et al. Blindsight depends on the lateral geniculate nucleus. *Nature*. 2010; 466(7304): 373-377. doi: [10.1038/nature09179](https://doi.org/10.1038/nature09179)

11. Bridge H, Hicks SL, Xie J, et al. Visual activation of extra-striate cortex in the absence of V1 activation. *Neuropsychologia*. 2010; 48: 4148-4154. doi: [10.1016/j.neuropsychologia.2010.10.022](https://doi.org/10.1016/j.neuropsychologia.2010.10.022)
12. Jones DK, Cercignani M. Twenty-five pitfalls in the analysis of diffusion MRI data. *NMR Biomed*. 2010; 23(7): 803-820. doi: [10.1002/nbm.1543](https://doi.org/10.1002/nbm.1543)
13. Farquharson S, Tournier JD, Calamante F, Fabbini G, et al. White matter fiber tractography: why we need to move beyond DTI. *J Neurosurg*. 2013; 118(6): 1367-1377. doi: [10.3171/2013.2.JNS121294](https://doi.org/10.3171/2013.2.JNS121294)
14. Kier EL, Staib LH, Davis LM, Bronen RA. MR imaging of the temporal stem: anatomic dissection tractography of the uncinate fasciculus, inferior occipitofrontal fasciculus, and Meyer's loop of the optic radiation. *AJNR Am J Neuroradiol*. 2004; 25(5): 677-691.
15. Peltier J, Vercllytte S, Delmaire C, et al. Microsurgical anatomy of the temporal stem: clinical relevance and correlations with diffusion tensor imaging fiber tracking. *J Neurosurg*. 2010; 112(5): 1033-1038. doi: [10.3171/2009.6.JNS08132](https://doi.org/10.3171/2009.6.JNS08132)
16. Rabbo AF, Koch G, Lefevre C, Seizeur R. Direct geniculo-extrastriate pathways: a review of the literature. *Surg Radiol Anat*. 2015; 37: 891-899. doi: [10.1007/s00276-015-1450-7](https://doi.org/10.1007/s00276-015-1450-7)
17. Tournier JD, Calamante F, Connelly A. Robust determination of the fibre orientation distribution in diffusion MRI: nonnegativity constrained super-resolved spherical deconvolution. *Neuroimage*. 2007; 35: 1459-1472. doi: [10.1016/j.neuroimage.2007.02.016](https://doi.org/10.1016/j.neuroimage.2007.02.016)
18. Tournier JD, Yeh CH, Calamante F, et al. Resolving crossing fibres using constrained spherical deconvolution: validation using diffusion weighted imaging phantom data. *Neuroimage*. 2008; 42: 617-625. doi: [10.1016/j.neuroimage.2008.05.002](https://doi.org/10.1016/j.neuroimage.2008.05.002)
19. Jeurissen B, Leemans A, Tournier JD, et al. Investigating the prevalence of complex fiber configurations in white matter tissue with diffusion magnetic resonance imaging. *Hum Brain Mapp*. 2013; 34: 2747-2766. doi: [10.1002/hbm.22099](https://doi.org/10.1002/hbm.22099)
20. Lim JC, Phal PM, Desmond PM, et al. Probabilistic MRI tractography of the optic radiation using constrained spherical deconvolution: a feasibility study. *PLoS One*. 2015; 10(3): e0118948. doi: [10.1371/journal.pone.0118948](https://doi.org/10.1371/journal.pone.0118948)
21. Martínez-Heras E, Varriano F, Prčková V, et al. Improved framework for tractography reconstruction of the optic radiation. *PLoS One*. 2015; 10(9): e0137064. doi: [10.1371/journal.pone.0137064](https://doi.org/10.1371/journal.pone.0137064)
22. Ferrera VP, Nealey TA, Maunsell JH. Responses in macaque visual area V4 following inactivation of the parvocellular and magnocellular LGN pathways. *J Neurosci*. 1994; 14(4): 2080-2088.
23. Ungerleider LG, Galkin TW, Desimone R, Gattass R. Cortical connections of area V4 in the macaque. *Cereb Cortex*. 2008; 18: 477-499. doi: [10.1093/cercor/bhm061](https://doi.org/10.1093/cercor/bhm061)
24. Duncan JS. Imaging in the surgical treatment of epilepsy. *Nat Rev Neurol*. 2010; 6: 537-550. doi: [10.1038/nrneurol.2010.131](https://doi.org/10.1038/nrneurol.2010.131)
25. Winston GP, Daga P, Stretton J, et al. Optic radiation tractography and vision in anterior temporal lobe resection. *Ann Neurol*. 2012; 71(3): 334-341. doi: [10.1002/ana.22619](https://doi.org/10.1002/ana.22619)
26. Piper RJ, Yoong MM, Kandasamy J, Chin RF. Application of diffusion tensor imaging and tractography of the optic radiation in anterior temporal lobe resection for epilepsy: a systematic review. *Clin Neurol Neurosurg*. 2014; 124C: 59-65. doi: [10.1016/j.clineuro.2014.06.013](https://doi.org/10.1016/j.clineuro.2014.06.013)
27. Cho JM, Kim EH, Kim J, et al. Clinical use of diffusion tensor image-merged functional neuronavigation for brain tumor surgeries: review of preoperative, intraoperative, and postoperative data for 123 cases. *Yonsei Med J*. 2014; 55(5): 1303-1309. doi: [10.3349/ymj.2014.55.5.1303](https://doi.org/10.3349/ymj.2014.55.5.1303)
28. Mormina E, Longo M, Arrigo A, et al. MRI tractography of corticospinal tract and arcuate fasciculus in high-grade gliomas performed by constrained spherical deconvolution: qualitative and quantitative analysis. *AJNR Am J Neuroradiol*. 2015; 36(10):

1853-1858. doi: [10.3174/ajnr.A4368](https://doi.org/10.3174/ajnr.A4368)

29. Arrigo A, Mormina E, Calamuneri A. The pre-surgical planning of brainneoplasms: from diffusion tensor imaging to more advanced approaches. *Radiol Open Journal*. 2015; 1(1): e1-e5.

30. Jellison BJ, Field AS, Medow J, et al. Diffusion tensor imaging of cerebral white matter: a pictorialreview of physics, fiber tract anatomy, and tumor imaging patterns. *AJNR Am J Neuroradiol*. 2004; 25(3): 356-369.

31. Dai H, Mu KT, Qi JP, et al. Assessment of lateral geniculate nucleus atrophywith 3T MR imaging and correlation with clinical stage of glaucoma. *AJNR Am J Neuroradiol*. 2011; 32(7): 1347-1353. doi: [10.3174/ajnr.A2486](https://doi.org/10.3174/ajnr.A2486)

32. El-Rafei A, Engelhorn T, Wärtges S, et al. Glaucoma classification based on histogram analysis of diffusion tensor imaging measures in the optic radiation. *ComputerAnalysis of Images and Patterns Lecture Notes in Computer Science*. 2011; 6854: 529-536.

33. Liu Y, Duan Y, He Y, et al. A tract-based diffusion study of cerebral white matter inneuromyelitis optica reveals widespread pathological alterations. *Mult Scler*. 2012; 18(7): 1013-1021. doi: [10.1177/1352458511431731](https://doi.org/10.1177/1352458511431731)