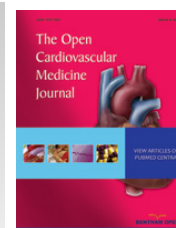



# The Open Cardiovascular Medicine Journal

Content list available at: [www.benthamopen.com/TOCMJ/](http://www.benthamopen.com/TOCMJ/)

DOI: 10.2174/1874192401610010044



## A Peculiar Case of a Floating Angio-Seal

R.C. Dettmers\*, W.M.P.F. Bosman, M.A.J. van den Broek, H.T.C. Veger, P.Ph.A. Hedeman Joosten and B.L.S. Borger van der Burg

Rijnland Hospital, Department of Surgery, Leiderdorp, the Netherlands

### Abstract:

#### Purpose

To show a complication of the use of an *Angio-Seal*<sup>TM</sup> closure device.

#### Case

We present a patient with a systolic murmur in his femoral artery after PCI. The murmur was caused by a dislocated *Angio-Seal*<sup>TM</sup>, a vascular closure device. This was diagnosed by Doppler Ultrasound. The device was surgically removed.

#### Conclusion

Vascular complications, such as lower limb ischemia, requiring surgical intervention tend to be higher after use of a vascular closure device. We advise routine physical examination of the puncture site after percutaneous closure with a vascular closure device, such as an *Angio-Seal*<sup>TM</sup>. The removal of the device can be performed *via* an open or endoscopic approach, based on available experience.

**Keywords:** Angio-Seal, complication, ischaemia, vascular closure device.

## INTRODUCTION

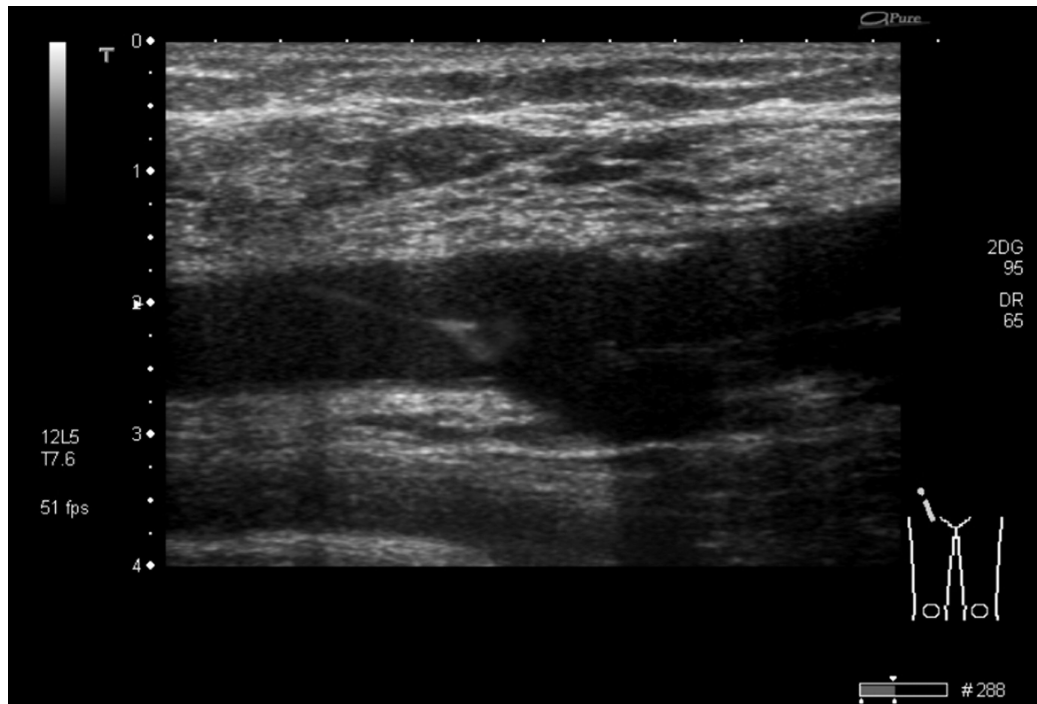
In this case we describe a complication caused by a dislocated *Angio-Seal*<sup>TM</sup> device after percutaneous intervention and how we approached this problem. We also provide a brief overview of the literature regarding this complication and possible solutions.

## CASE

A 63-year-old man had been subjected to a percutaneous coronary intervention *via* his right femoral artery. At the end of the uncomplicated procedure, the puncture site was closed using an *Angio-Seal*<sup>TM</sup> (St Jude Medical, Minnesota, USA). The patient had no post-interventional complaints of pain in his lower limb and there were no signs of limb ischemia. Routine physical examination of the puncture site revealed a systolic murmur over his right femoral artery. An arterial Doppler ultrasound was made, which showed a mobile structure floating in the common femoral artery (Fig. 1, video 1). It was hypothesized that the *Angio-Seal*<sup>TM</sup> had dislocated after the procedure and was now floating in the common femoral artery. Considering the risk of arterial thrombosis or dislodgement and thereby possibly embolization to the popliteal or crural arteries, there was an indication for surgical removal of the *Angio-Seal*<sup>TM</sup>. After adequate exposure and vascular control of the common femoral artery, superficial and deep femoral artery, a longitudinal incision was made in the common and superficial femoral artery and the *Angio-Seal*<sup>TM</sup> was removed entirely (Fig. 2). The longitudinal incision was closed primary with prolene stitches, taking care that no stenosis occurred. A postoperative Doppler ultrasound showed no stenosis and a normal flow pattern. The patient was discharged without any clinical

\* Address correspondence to this author at the Rijnland Hospital Leiderdorp, Simon Smitweg 1, 2353 GA Leiderdorp, Netherlands; Tel: 0031629731080; Email: [r.dettmers@rijnland.nl](mailto:r.dettmers@rijnland.nl)

symptoms or complications on the second postoperative day. Patient consent was obtained for publishing this case.



**Fig. (1).** Ultrasound of the common femoral artery, showing the luxated anchor of the *Angio-Seal*<sup>TM</sup>, floating in the lumen, hanging on the suture from the vessel wall.



**Fig. (2).** The *Angio-Seal*<sup>TM</sup> was surgically removed through a vertical incision of the common femoral artery.

## DISCUSSION

An *Angio-Seal*<sup>TM</sup> is a bio-absorbable arterial closure device that is placed after a percutaneous intervention to achieve haemostasis and prevent extra-luminal bleeding. The aim of this device is earlier mobilisation, which reduces hospital admission duration and consequently, medical costs. It consists of three parts; an intra-arterial bio-absorbable anchor, a suture and an extra-arterial collagen sponge to seal the vessel. The sponge should be pushed over the suture to attain compression to the outside of the arterial wall, thereby pulling the intraluminal anchor to the inside of the vessel wall in order to fully close the puncture hole. The anchor and suture completely dissolve within 90 days [5]. In this specific case, the collagen sponge was probably not pressed firmly enough to the outer arterial wall during *Angio-Seal*<sup>TM</sup> placement, enabling the anchor to luxate and float in the common femoral artery (Fig. 1). The suture on the anchor prevented dislodgement of the anchor and consequent symptoms of limb ischemia.

A literature search was conducted to identify common complications of the use of vascular closure devices, such as an *Angio-Seal*. Complications that were most frequently encountered included groin bleeding, arterial stenosis and infection [1]. A large meta-analysis [1] comparing vascular closure devices with manual or mechanic compression after coronary angiography or percutaneous intervention showed that lower limb ischemia and other ischemic arterial complications (0.3% *versus* 0.0%,  $p=0.07$ ), the need of surgery for vascular complications (0.7% *versus* 0.4%,  $p=0.10$ ) and the risk of groin infection (0.6% *versus* 0.2%,  $p=0.02$ ) tended to be higher in the vascular closure device groups. For *Angio-Seal* patients only, the risk of arterial stenosis, limb ischemia or device luxation was comparable to patients with manual or mechanic compression (RR 3.00, 95% CI 0.12-73.35). The risk of arterial complications that required vascular surgery was also not significantly higher in the intervention-group using an *Angio-Seal*<sup>TM</sup> (RR 1.00, 95% CI 0.17-5.74).

There are several techniques to remove a luxated vascular closure device [2 - 4]. Recently, Boersma *et al.* [4] described a case in which a luxated *Angio-seal*<sup>TM</sup> was removed with an endovascular Alligator Tooth Retrieval Forceps in the distal femoral artery. Two other cases describe patients who needed vascular surgery to remove the luxated device similar to the case described in this article [2, 3]. We chose a surgical approach because of the risk of distal embolization and lack of experience in removing a luxated *Angio-Seal*<sup>TM</sup> with an endovascular technique.

## CONCLUSION

Dislocation of an *Angio-Seal*<sup>TM</sup> closure device is a rare complication, which normally requires an intervention to prevent embolism, arterial thrombosis or limb ischemia. The removal of the device can be performed *via* an open or endoscopic technique, based on available experience and preference. Physicians using an *Angio-Seal*<sup>TM</sup> should be aware that inadequate pressure of the *Angio-Seal*<sup>TM</sup> firmly to the vessel wall could potentially result in its potential dislocation. Current manuscript displays distinctive ultrasound imaging of the floating *Angio-Seal*<sup>TM</sup> in the common femoral artery. We advise routine physical examination of the puncture site after percutaneous closure to assess presence of a systolic murmur prior to discharge.

## CONFLICT OF INTEREST

The authors confirm that this article content has no conflict of interest.

## ACKNOWLEDGEMENTS

Video 1. Ultrasound of the common femoral artery, showing the luxated anchor of the *Angio-Seal*<sup>TM</sup>, floating in the lumen, hanging on the suture from the vessel wall.

## REFERENCES

- [1] Biancari F, D'Andrea V, Di Marco C, Savino G, Tiozzo V, Catania A. Meta-analysis of randomized trials on the efficacy of vascular closure devices after diagnostic angiography and angioplasty. *Am Heart J* 2010; 159(4): 518-31. [<http://dx.doi.org/10.1016/j.ahj.2009.12.027>] [PMID: 20362708]
- [2] Prabhudesai A, Khan MZ. An unusual cause of femoral embolism: angioseal. *Ann R Coll Surg Engl* 2000; 82(5): 355-6. [PMID: 11041042]
- [3] Ainslie MP, Macdonald J, Smyth J. A pain in the leg following angiography. *J Invasive Cardiol* 2011; 23(3): E58-60. [PMID: 21364253]
- [4] Boersma D, van Strijen MJ, Kloppenburg GT, van den Heuvel DA, de Vries JP. Endovascular retrieval of a dislodged femoral arterial closure device with Alligator forceps. *J Vasc Surg* 2012; 55(4): 1150-2. [<http://dx.doi.org/10.1016/j.jvs.2011.12.015>] [PMID: 22265797]

[5] Angio-Seal Evolution Vascular Closure Device Brochure. St. Jude Medical. Available from: <http://professional.sjm.com/products/-vas/hemostasis-management/vascular-closure-devices/angio-seal-evolution#overview>

---

Received: June 22, 2015

Revised: August 20, 2015

Accepted: September 22, 2015

© Dettmers *et al.*; Licensee *Bentham Open*.

This is an open access article licensed under the terms of the Creative Commons Attribution-Non-Commercial 4.0 International Public License (CC BY-NC 4.0) (<https://creativecommons.org/licenses/by-nc/4.0/legalcode>), which permits unrestricted, non-commercial use, distribution and reproduction in any medium, provided the work is properly cited.